RETINOBLASTOMA

1. Important facts
2. Presentation
3. Signs
   - Endophytic
   - Exophytic
4. Treatment
5. Poor prognostic factors
6. Histology
7. Differential diagnosis of leukocoria

Important facts

1. Most common primary, malignant, intraocular tumour of childhood (1:20,000)
2. No sexual predilection
3. Presents before age of 3 years (average 3 months)
4. Heritable (40%) or non-heritable (60%)
5. Predisposing gene (RPE 1) on 13q14

Presentations of retinoblastoma

• Leukocoria - 60%

• Strabismus - 20%

• Secondary glaucoma

• Anterior segment invasion

• Orbital inflammation

• Orbital invasion

Early endophylitic retinoblastoma

White flat lesion

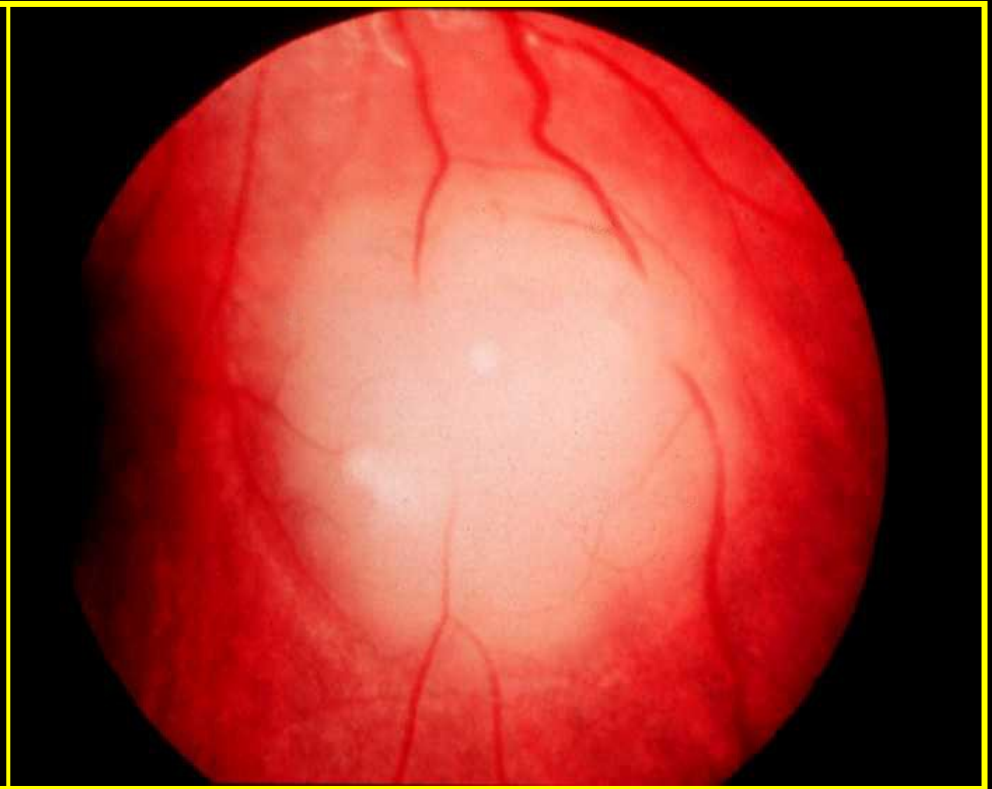

Placoid lesion

More advanced endophytic retinoblastoma

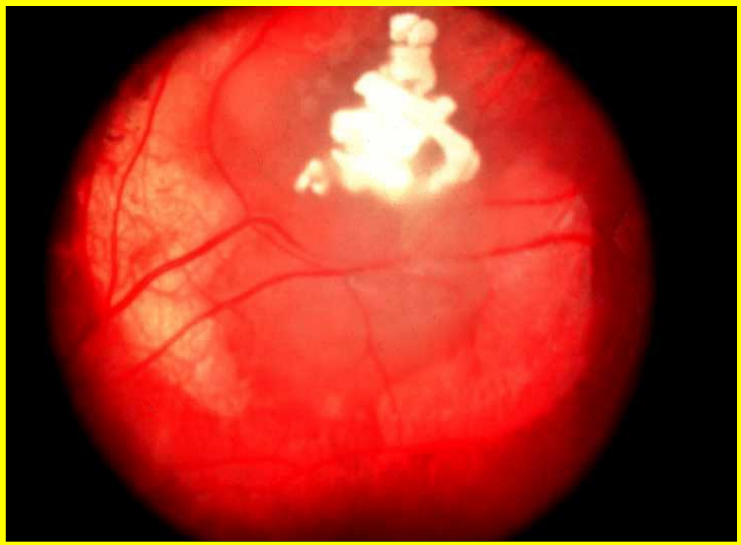

Friable white mass

Cottage cheese appearance

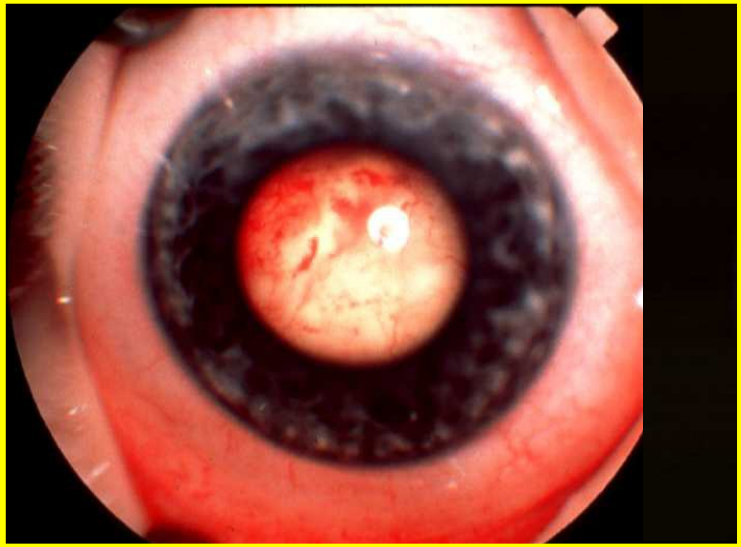

Fine surface blood vessels

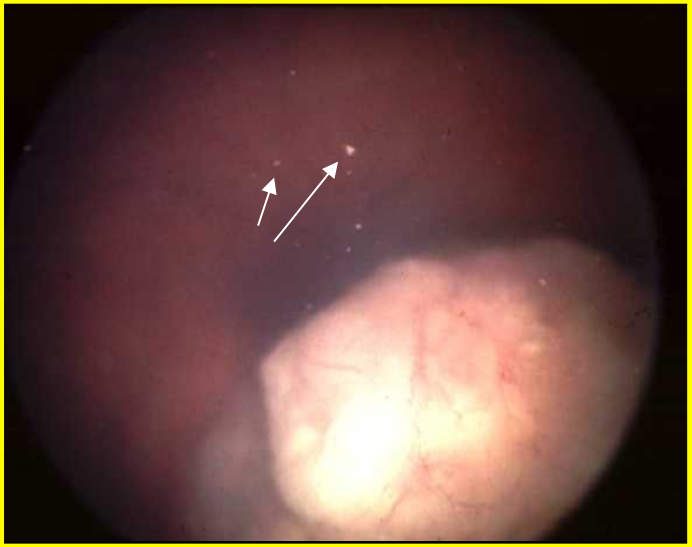

Vitreous seedings

Exophytic retinoblastoma

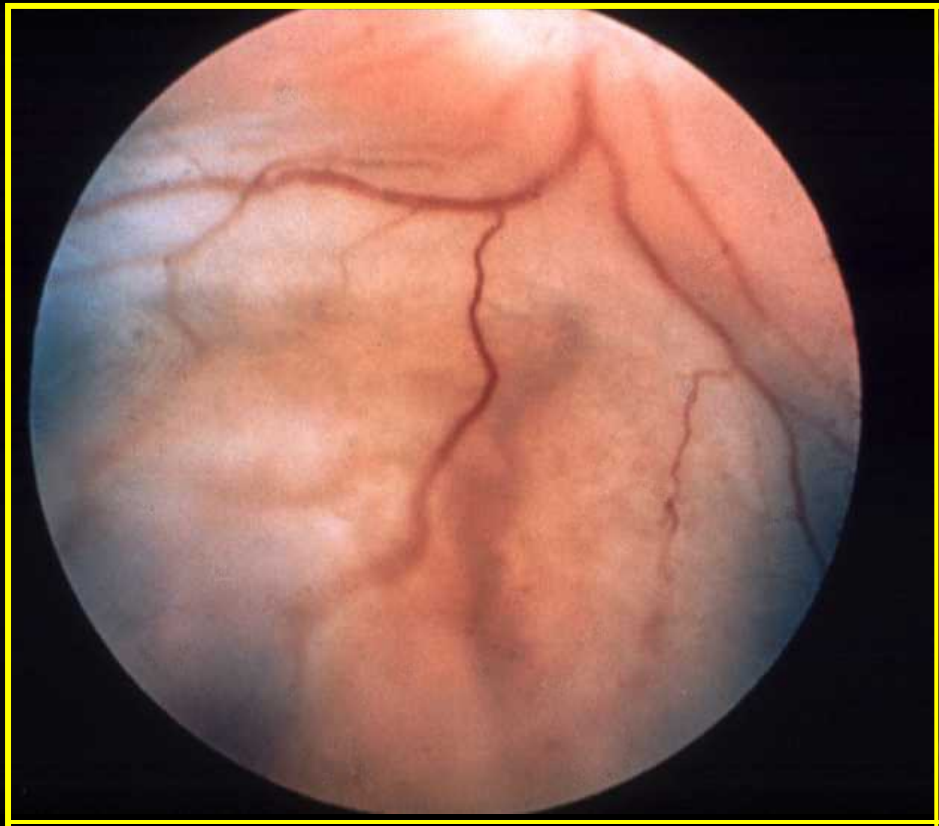

Multiglobulated white mass with overlying retinal detachment

May be difficult to visualize through deep detachment

CT diagnosis of retinoblastoma

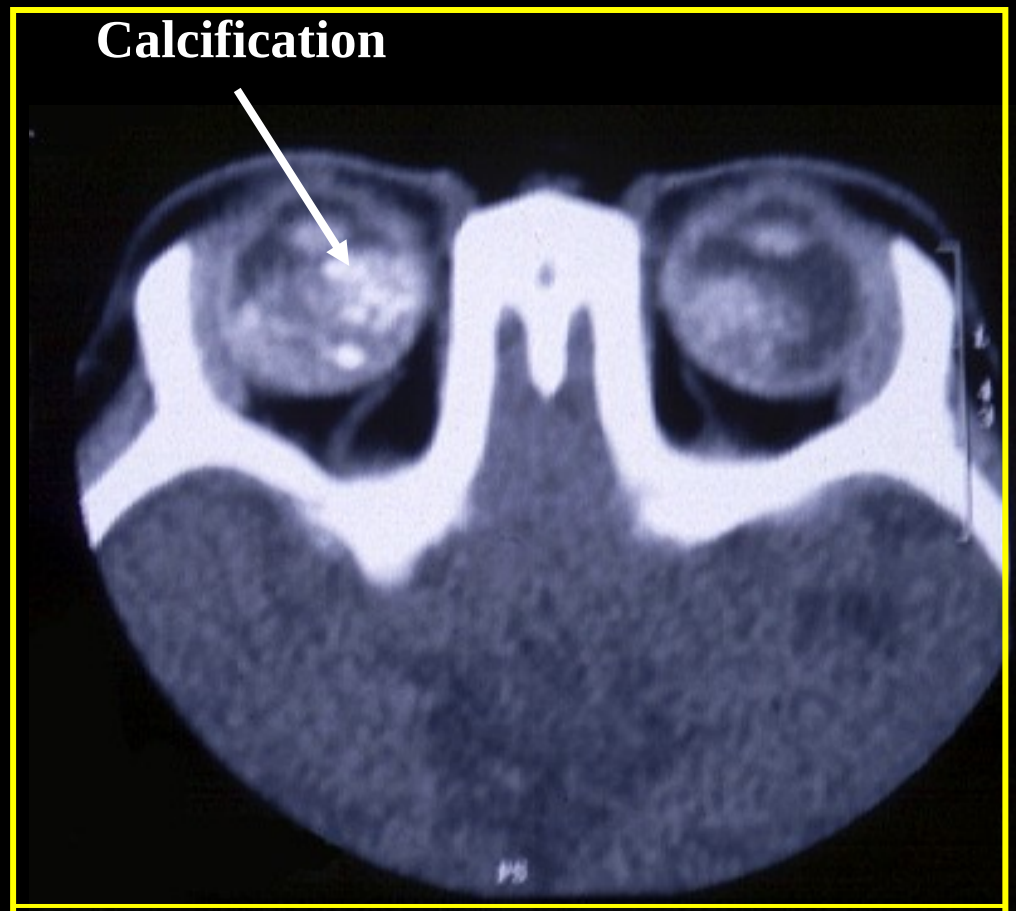

- Optic nerve involvement
- Orbital and CNS extension
- Pinealoblastoma

Treatment Options of Retinoblastoma

1. **Small tumours**
   - Laser photocoagulation
   - Transpupillary thermotherapy
   - Cryotherapy
2. **Medium tumours**
   - Brachytherapy
   - Chemotherapy
   - External beam radiotherapy
3. **Large tumours**
   - Chemotherapy followed by local treatment
   - Enucleation
4. **Extraocular extension**
   - External beam radiotherapy
5. **Metastatic disease**
   - Chemotherapy

Poor Prognostic Factors in Retinoblastoma

1. Optic nerve involvement
2. Choroidal invasion
3. Large tumour
4. Anterior location
5. Poor cellular differentiation
6. Older children

Histology of retinoblastoma

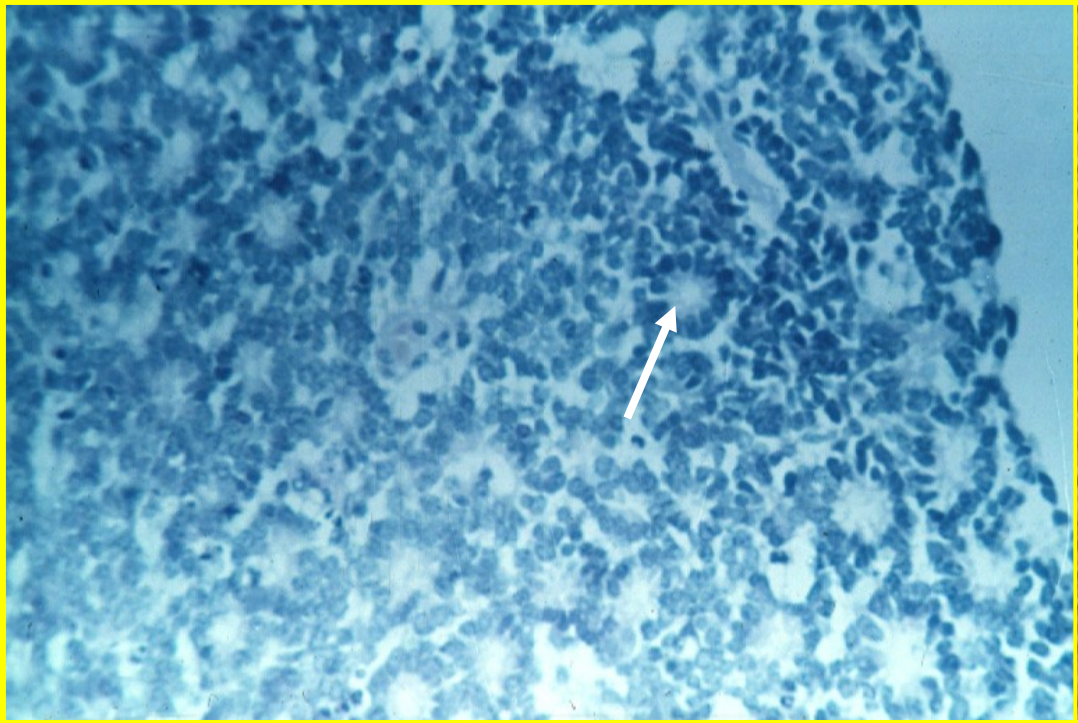

Well-differentiated with many Flexner-Wintersteiner rosettes

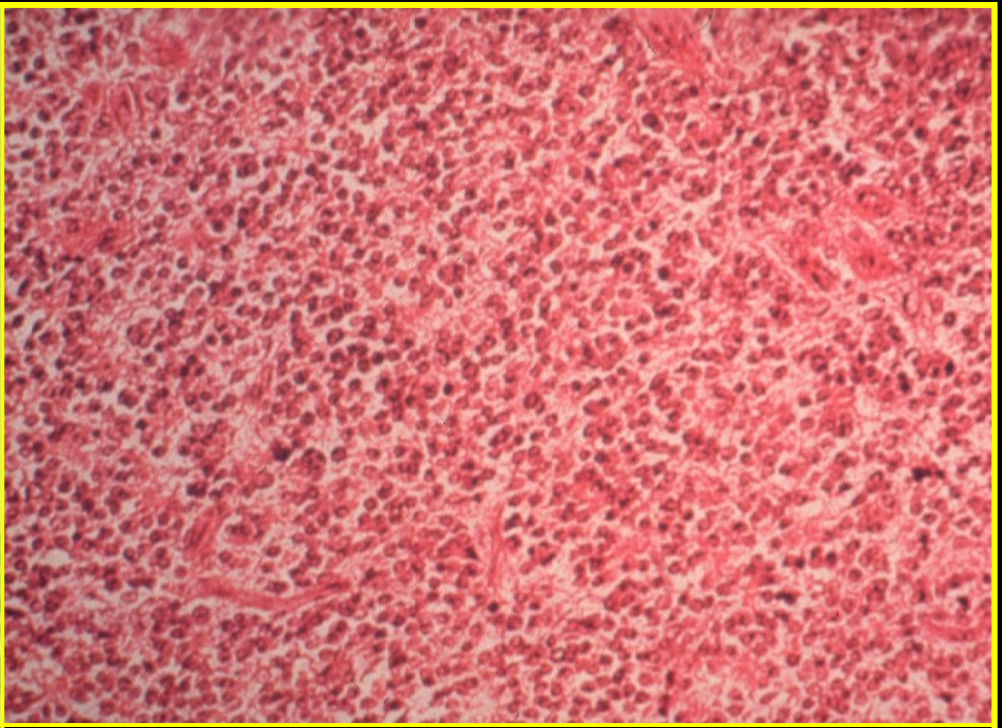

Poorly differentiated

Differential diagnosis of leukocoria

Congenital cataract	Persistent hyperplastic primary vitreous	Inflammatory cyclitic membrane
		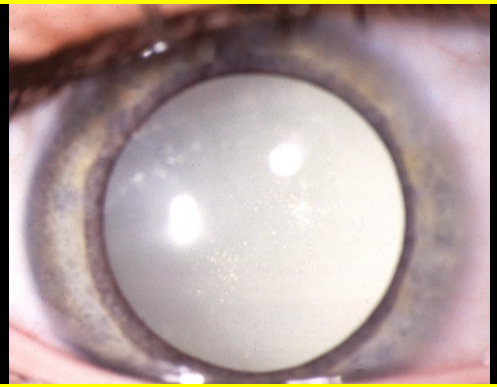
Unilateral or bilateral	Unilateral	Unilateral or bilateral
Coats disease	**Posterior pole toxocara granuloma**	**Advanced retinopathy of prematurity**
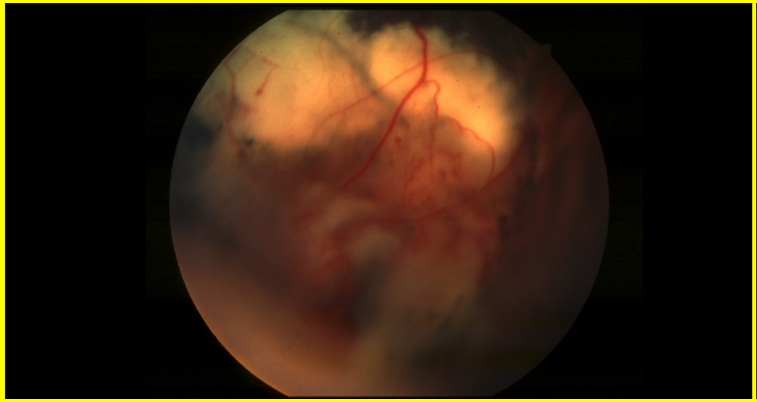		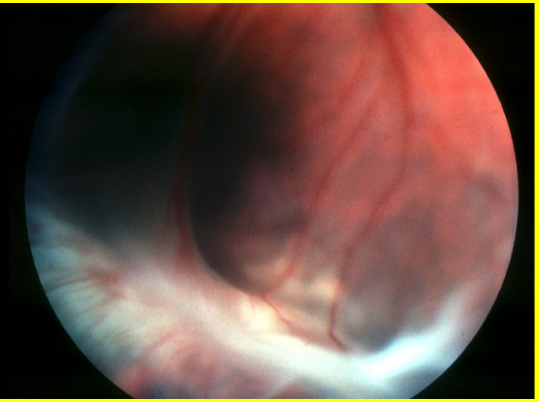
Unilateral	Unilateral	Always bilateral but may be asymmetrical